

A COMPARATIVE STUDY OF VARIOUS MODALITIES IN THE MANAGEMENT OF FISTULA IN ANO

Dr. Avinash Sharma*, Dr. Prakhar Nagar, Dr. Vipul Jain, Dr. Anjali Chitale

Asst. Prof. MGMCHRC, Jaipur.

Prof. SMBTMSRC, Nashik.

Article Received: 14 April 2026 | Article Revised: 05 May 2026 | Article Accepted: 25 May 2026

*Corresponding Author: Dr. Avinash Sharma

Jaipur.

DOI: <https://doi.org/10.5281/zenodo.20460625>

How to cite this Article: Dr. Avinash Sharma, Dr. Prakhar Nagar, Dr. Vipul Jain, Dr. Anjali Chitale (2026) A COMPARATIVE STUDY OF VARIOUS MODALITIES IN THE MANAGEMENT OF FISTULA IN ANO. World Journal of Pharmaceutical Science and Research, 5(6), 533-538.



Copyright © 2026 Dr. Avinash Sharma | World Journal of Pharmaceutical Science and Research.

This work is licensed under creative Commons Attribution-NonCommercial 4.0 International license (CC BY-NC 4.0).

ABSTRACT

Background: Fistula in ano is a track that connects deeply the anal canal or rectum to the skin around the anus. Fistula in ano most commonly follows an anorectal sepsis¹. The main principles of management of anal fistula are closure of internal opening of fistula tract, drainage of infection or necrotic tissue, and eradication of fistulous tract with preservation of sphincter function. The objectives were to compare the various aspects like per operative complications, post-operative complications, mean hospital stay in the treatment of fistula in ano using various modalities like fistulotomy, fistulectomy, setons and lift procedure. **Methods:** This is a randomised, comparative, prospective study of 80 cases of fistula in ano, presenting at surgical opd of MGMCHRC Jaipur Out of which, 20 cases are treated by fistulectomy, 20 by seton, 20 by fistulotomy and the rest 20 cases by LIFT procedure by random selection method, during period of NOVEMBER 1, 2024 to 31st October 2025. **Results:** Most common age of presentation is 31-40 years and more common in males than females (M: F= 2.3:1). Per operative complications include bleeding seen more in patients undergoing fistulectomy. Per operative course of LIFT procedure patients was complication free. Postoperative pain seen more in patients undergoing setons procedure. **Conclusions:** we conclude that LIFT procedure and Fistulotomy were acceptable procedures for simple, uncomplicated low lying and high lying fistula.

KEYWORDS: Fistulotomy, Fistulectomy, LIFT procedure, Setons.

INTRODUCTION

Fistula is an abnormal connection between two hollow organs or between hollow organ and the skin lined by epithelial tissue. In cases of fistula in ano, it is a track that connects deeply the anal canal or rectum to the skin around the anus.

The primary opening is deep in the anal canal or rectum and the superficial openings, which may be multiple, are around the perianal skin. Being a common surgical condition, fistula in ano most commonly follows an anorectal sepsis, puts a surgeon in challenging situation to decide about best option for the patient and to satisfy the patient.^[1]

The main principles of management of anal fistula are closure of internal opening of fistula tract, drainage of infection or necrotic tissue, and eradication of fistulous tract with preservation of sphincter function.^[2] Studies have revealed that high fistulae have low incidence. Low fistulae are the commonest anal fistulae and can be treated easily by conventional laying-open technique. High fistula-in-ano are difficult to treat since the conventional laying-open will lead to division of most of the anal sphincter muscles resulting in incontinence. To achieve the objective in high anal fistulae, different surgical techniques have been described in literature from time to time. These include Park's fistulotomy, insertion of a seton, two-stage fistulotomy, primary fistulectomy with occlusion of the internal ostium, fistulotomy with primary repair of the sphincter, endorectal advancement flaps, anocutaneous advancement flap, repair of fistula using fibrin adhesive glue and re-routing the fistula.

Anorectal fistulas are divided into four distinct types according to the Parks' classification: intersphincteric, trans-sphincteric, suprasphincteric, and extrasphincteric. The ultimate goal of fistula surgery is to eradicate it without disturbing or disturbing minimally the anal sphincter mechanism. Hippocrates in 460 BC, first described the seton usage in the treatment of fistula in ano. Ayurvedically medicated seton, "kshara" was used by sushruta for treating fistula in ano. Lay open technique for fistula in ano was first described in 1337 by John of Arderene.

Barber surgeon Charles Felix in 1636, treated king Louis XIV with fistulotomy for fistula in ano. Frederik Salmon in 1835, founded Saint Marks Hospital primarily for the treatment of fistula in ano. He recommended a cut back technique to fistulous tract triangular, when it is laid open, so that mucosal edge healed earlier than skin wound.

In British journal of surgery, Parks A.G. et al based on the level of fistula with respect to sphincter, classified fistula in ano into four types. In article published in Germany, Strittmatter B, described various forms of fistula establishing the entire course of the tract was the important factor in achieving cure of the disease and most of the fistula can be treated by fistulotomy or fistulectomy when tract is established.

In present study we compare the various aspects in the treatment of fistula in ano using various modalities as fistulotomy, fistulectomy, setons and lift procedure.

Fistulotomy

Fistulotomy means laying open or unroofing of the fistulous tract. After retracting the anal canal, blunt ended probe is introduced through the external opening upto internal opening. Tissue that overlying the probe is divided. Then epithelial lining of the fistulous tract is curetted. Overhanging skin edges excised. If there is any additional tract identified, it is also laid open. Saline gauze is packed initially. Sitz bath is advised later.^[4]

Fistulectomy

Surgery was done under spinal anaesthesia. An elliptical incision is made around the external opening and deepened, and tissue dissected in either side of the tract. When methylene blue dye is injected, it acts as a guide that prevents the fistulous tract from accidental injury. If sphincter muscles come across during dissection, it is separated from the tract.

Dissection completed upto internal opening and finally mucosal defect closed with delayed absorbable suture materials. Sometimes tract ends abruptly and without internal opening, in such cases dissection completed upto the level of methylene blue staining and tract excised. It is also done in three stages of dissection.^[5,6]

Seton Treatment

Three types of treatment are Cutting, Draining and Medicated SETON. It is useful in treating high anal fistula. Thin silastic tubing/ monofilament non-absorbable material is used. Patient in lithotomy position, internal and external openings identified with blunt probe. Then the SETON is passed through the external opening through the fistulous tract into internal opening and the end was brought out through anal canal. Then the two ends knotted parallel with silk to avoid discomfort to the patient. Rodder's knot is used for this purpose. In case of cutting SETON, after a period of two weeks, the seton is gradually tightened, so as to cut through the anal sphincter progressively. Draining seton is kept for two to three months to drain collection and to control infection. In case of medicated seton, ayurvedic medication increases cutting rate 1 cm per week, with mean cut out time is around 8.3 weeks.^[7]

Lift Procedure

Ligation of inter sphincteric fistulous tract. It is the simplest procedure with low recurrence rate and no anal incontinence. A 2cm incision is made parallel to anal verge in the inter sphincteric groove, inter sphincteric plane between external and internal anal sphincter is reached. Fistulous tract is identified and hooked out. Then wound sutured in layers.^[8-11]

Fibrin Glue

Fibrin glue is mixture of fibrinogen, thrombin and calcium ion. When injected into the fistulous tract, it combines and forms fibrin clot by conversion of fibrinogen into fibrin. After 7 to 14 days of injection, tract is converted and filled with synthetic collagen.^[12]

Fibrin Plug

It was first used in 2006 for anal fistula. Lipophilised small intestinal submucosa of the porcine is used. It is a conical shaped plug maintains stability within the fistulous tract prevents dislodgement during defecation.

Endo Advancement Flap

Fistulous tract is identified, and internal opening excised. Defect is then closed with advancement flap. The flap contains rectal mucosa, submucosa and part of the internal sphincter. The flap has an apex and base. The base of the flap is twice as thick as apex, placed beyond closed mucosal defect

Stem Cell Therapy

Adipose derived stem cells used. It is successfully used in complex anal fistula, results are promising.

METHODS

This is a randomised, comparative, prospective study of 80 cases of fistula in ano, presenting at surgical opd of MGMCHRC Jaipur. Out of which, 20 cases are treated by fistulectomy, 20 by seton, 20 by fistulotomy and the rest 20 cases by LIFT procedure by random selection method, during period of NOVEMBER 1, 2024 to 31st October 2025 Clinical history and Clinical examination including per rectal and proctoscopic examination was done in all the

patients. All the patients were processed by routine investigations, chest X-ray etc., prior to surgery. Pus culture sensitivity and Fistulogram was done in all cases. C.T. Scan and M.R fistulogram as per requirement. All patients, of age 20-60 yr with fistula in ano attending surgical OPD between NOVEMBER 1, 2024 to 31st October 2025 were included in the study. Patients with other anorectal diseases, Ca rectum & IBD, crohn's disease, recurrent fistula in ano, less than 20 year and more than 60-year, other co-morbid condition like CCF, uncontrolled DM, and immuno-compromised status were excluded.

RESULTS

Out of 80 patients included in this study, most common age of presentation is 31-40 years and more common in males than females (M:F = 2.3:1). 60 (75%) patients give previous history of incision and drainage done for perianal abscess out of which history of incision and drainage done within 1 year of presentation of fistula in ano in 36 (45%) of the patients.

Per operative complications include bleeding seen in 4 (20%) patients undergoing fistulotomy, 7 (35%) patients was complication free. Post-operative complications include bleeding seen in 3 (15%) patients of fistulotomy and 4 (20%) patients of fistulectomy with no post-operative bleeding seen in patients with setons and LIFT procedure. Post-operative pain seen in 7 (35%) patients undergoing setons procedure and 5 (25%) patients undergoing fistulectomy. patients undergoing fistulectomy and 1 (5%) patient of seton's procedure. Sphincter injury seen in 4 (20%) patients of fistulotomy and 3 (15%) patients undergoing fistulectomy. Per operative course of LIFT procedure Post-operative fever and wound infection seen in 3 (15%) patients each of fistulectomy and fistulotomy. The number of patients with post-operative fever and wound infection is quite low about 1 (5%) each in patients undergoing setons and LIFT procedure in present study.

On long term follow up chronic pain seen maximum in patients undergoing setons procedure about 6(30%) followed by 4 (20%) and 3 (15%) patients undergoing fistulotomy and fistulectomy respectively.

DISCUSSION

Fistula in ano is very common surgical problem, posing great challenge in treatment. There are many treatments available at present namely fistulectomy, fistulotomy,

Recurrence seen in 5 (25%) cases of fistulectomy followed by 3 (15%) patients in LIFT procedure and 2 (10%) each in fistulotomy and setons respectively.

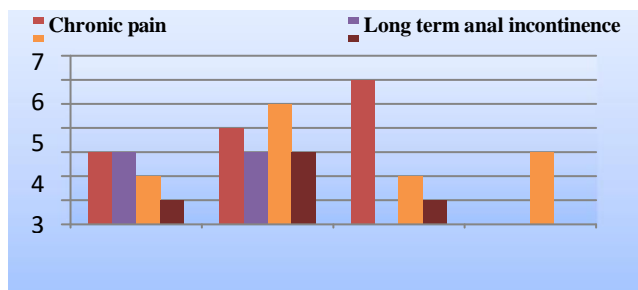
LIFT, seton technique. As each procedure is associated with its own complications this study done here to compare the outcome of various surgeries of fistula in ano in terms of complications, duration of surgery, post-operative hospital stays. Patient satisfaction depends on factors like postoperative hospital stay, postoperative pain and bleeding, return to routine activity, wound healing time, interference with the anal continence and most importantly the recurrence of the disease.

The maximum number of cases of fistula in ano are found in the age group of 31-40 years with a Male: Female ratio of 2.3:1, which is comparable with other similar studies Quazi et al and Yasmin Bhatti et al.^[15,16] Perianal discharge being the most common presenting symptom as found in R.N Mangul et al^[17] Post-operative bleeding was more among fistulectomy group about 20% compared to 0% in seton group because seton technique uses technique of pressure

which is a slow and gradual process.

The major worry for the patient and the surgeon in fistulectomy is incontinence which was about 5%, which was a minor incontinence only to flatus in fistulectomy group and there was absolutely zero number of incontinence with seton group, supporting the results of various other studies.^[19-22] Post-operative pain seen in 7(35%) patients undergoing setons procedure and 5(25%) patients undergoing fistulectomy, results are comparable with other studies.

In Poon Chi-Ming et al study (135 patients), there was recurrence in 13.3% of patients operated by fistulectomy compared to present study of 25% recurrence operated by fistulectomy.



CONCLUSION

Fistulotomy has moderate intra operative and post-operative complication with less chance of anal incontinence and stricture with least chance for recurrence. Fistulectomy has moderate degree of intra operative and post-operative complications with moderate chance for recurrence, Stricture and incontinence moreover few cases required second setting for the completion of treatment Even though SETON treatment has no intra operative complications, less recurrence rate and incontinence rate. It has more post-operative complications like post-operative pain, high degree of inconvenience to the patient. It is a multistage procedure. We need intense cooperation and long term follow up and treatment of the patients for success. Lift procedure least or literally no intra operative or post-operative complication, with very short hospital stay, no risk of anal incontinence or stricture and mild risk of recurrence. Patient was able to proceed normal day to day life as soon as possible without inconvenience. So, we conclude that LIFT procedure and Fistulotomy were acceptable procedures for simple, uncomplicated low lying and high lying fistula.

REFERENCES

1. Henrichsen S, Christiansen J., Incidence of fistula-in-ano complicating anorectal sepsis: a prospective study, Br J Surg. 1986 May; 73: 371-2.
2. Mc Courtney J.S, Finlay I.G. Setons in the surgical management of fistula in ano. British Journal Surgery, 1995; 82: 448-52.
3. Gurer A, Ozlem N, Gokakin AK, Ozdogan M, Kulacoglu H, Aydin R. A novel material in seton treatment of fistula-in-ano. American Journal of surgery, 2007; 193: 794-6.
4. Tang GL, Chew SP, Seow-Choen F. Prospective randomized trial of drainage alone vs drainage and fistulotomy for acute perianal abscesses with proven internal opening. Dis. Colon Rectum, 1996; 39: 1415-17.
5. Jivapaisarnpong P. Core out fistulectomy, anal sphincter reconstruction J Med Assoc Thai, 2009; 92: 638-42.
6. Miller GV, Finan PJ. Flap advancement and core fistulectomy for complex rectal fistula. Br J Surg, 1998; 85: 108-10.

7. Tan KK, Tan IJ, Lim FS, Koh DC, Tsang CB. The anatomy of failures following the ligation of intersphincteric tract technique for anal fistula, 2011; 54: 1368-72.
8. Bleier JI, Moloo H, Goldberg SM. Ligation of the intersphincteric fistula tract: an effective new technique for complex fistulas. *Dis Colon Rect*, 2010; 53: 43-6.
9. Shanwani A, Nor AM, Amri N. Ligation of the intersphincteric fistula tract (LIFT): a sphincter-saving technique for fistula-in-ano. *Dis Colon Rect.*, 2010; 53: 39-42.
10. Jarrar A, Church J. Advancement flap repair *Dis Colon Rectum*, 2011; 54: 1537-41.
11. Ho KS, Tsang C, Seow-Choen F, Ho YH, Tang CL, Heah SM, Eu KW. Comparing ayurvedic cutting seton and fistulotomy for low fistula-in-ano. *Tech Coloproctol*, 2001; 5: 137-41.
12. Han JG, Wang ZJ, Zhao BC, Zheng Y, Zhao B, Yi BQ et al. Long-term outcomes of human acellular dermal matrix plug in closure of complex anal fistulas with a single tract. *Dis Colon Rect*, 2011; 54: 1412-8.
13. Abbas MA, Lemus-Rangel R, Hamadani A. Long-term outcome of endorectal advancement flap for complex anorectal fistulae. *Am Surg*, 2008; 74: 921-4.
14. Razaque AQ, Memon JM, Solangi RA, Qaiser S, Nauqvi H. Outcome analysis of partial fistulotomy with seton. *Pak J Surg*, 2008; 24: 15-8.
15. Bhatti Y, Fatima S, Shaikh GS, Shaikh S. Fistulotomy versus fistulectomy in the treatment of low fistula in ano. *Raw Medi J.*, 2011; 36: 1-8.
16. R.N. Mangual, D.N. Tudu, S.P. Pattaik, K.P. Prusty. The sphincter preserving perianal fistulectomy: A better alternative. *Ind J Surg*, 2004; 66: 31-5.
17. Theerapol A, SO BYJ, Ngoi SS. Routine use of setons for the treatment of anal fistulae. *Singapore Medicine J.*, 2002; 43: 305-7.
18. Deshpande PJ, Sharma KR, Sharma SK, Singh LM. Ambulatory treatment of fistulo-in-ano: results in 400 cases. *Indian J Surg*, 1975; 37: 85-9.
19. Fasth SB, Nordgren S, Hultén L. Clinical course and management of suprasphincteric and extrasphincteric fistula-in-ano. *Acta Chir Scand*, 1990; 156: 397-402.
20. Gonzalez-Ruiz C, Kaiser AM, Vukasin P et al. Intraoperative physical diagnosis in the management of anal fistula. *Am Surg*, 2006; 72: 11-5.
21. Hamel CT, Marti WR, Oertli D. Simplified placement and management of cutting setons in the treatment of transsphincteric anal fistula: technical note. *Int J Colorectal Dis.*, 2004; 19: 354-6.
22. Poon CM, Dennis CK, Cheung MH, Raymond SK, Leong HT; Recurrence Pattern of Fistula-in-Ano; *J Gastrointest Liver Dis.*, 2008; 17: 53-7.