World Journal of Pharmaceutical Science and Research

www.wjpsronline.com

Case Report

ISSN: 2583-6579
SJIF Impact Factor: 6.916
Year - 2026
Volume: 5; Issue: 11
Page: 31-39

PANCHAKARMA IN IDIOPATHIC BASAL GANGLIA CALCIFICATION: FROM RIGIDITY TO RECOVERY – A CASE REPORT

Dr. Swaruprani Sethi*[1], Dr. Doddabasayya[2]

[1]Final year PG Scholar, Dept of Panchakarma, Government Ayurveda Medical College, Bengaluru.

[2]HOD & Professor, Dept of Panchakarma, Government Ayurveda Medical College, Bengaluru.

Article Received: 14 September 2026 | | ***Article Revised: 05 October 2026*** | | ***Article Accepted: 26 October 2026***

***Corresponding Author: Dr. Swaruprani Sethi**
Final year PG Scholar, Dept of Panchakarma, Government Ayurveda Medical College, Bengaluru.
DOI: https://doi.org/10.5281/zenodo.23798488

How to cite this Article: Dr. Swaruprani Sethi, Dr. Doddabasayya (2026) PANCHAKARMA IN IDIOPATHIC BASAL GANGLIA CALCIFICATION: FROM RIGIDITY TO RECOVERY – A CASE REPORT. World Journal of Pharmaceutical Science and Research, 5(11), 31-39.

Copyright © 2026 Dr. Swaruprani Sethi | World Journal of Pharmaceutical Science and Research.
This work is licensed under creative Commons Attribution-NonCommercial 4.0 International license (CC BY-NC 4.0).

ABSTRACT

Familial idiopathic basal ganglia calcification is also known as Fahr's syndrome, Fahr's disease and primary familial brain calcification. It is a rare neurological disorder characterized by bilateral calcifications of areas in the brain including, basal ganglia (most commonly the globus pallidus), cerebellum (most commonly the dentate nucleus), thalamus, hippocampus, cerebral cortex. Clinical manifestations of this disease incorporate a wide variety of symptoms, ranging from neurological symptoms of extrapyramidal system to neuropsychiatric abnormalities of memory and concentration to movement disorders including Parkinsonism and tremors amongst others. Fahr's syndrome is a functional neurological disorder and the pathogenesis starts due to long term use of antiepileptic medications and emotional triggering factor. Based on pathogenesis and clinical features, can be studied under heading of *Vatavyadhi (Akshepaka)* & *Kampavata*. This case underscores the potential of Ayurvedic management as a holistic, safe, and efficacious approach for Fahr's Syndrome, offering promising avenues for integrated healthcare.

KEYWORDS: Fahr's syndrome, Calcification, *Kampavata*, *Abhyanga*, *Nasya*.

INTRODUCTION

Fahr's Syndrome, first described by Karl Theodor Fahr in 1930, its prevalence is <1/1,000,000. The clinical spectrum is highly variable and includes extrapyramidal movement disorders like parkinsonism, chorea, tremor, dystonia, ataxia, dysarthria, cognitive impairment, and neuropsychiatric manifestations like psychosis, mood disorders and memory loss. Conventional management remains symptomatic with antiparkinsonian, antiepileptic and antipsychotic drugs, with no definitive cure to halt calcification. In Ayurveda, there is no direct description of Fahr's Syndrome, but based on its clinical presentation, it can be understood under the spectrum of *Vata Vyadhi*. When the disease is dominated by motor

symptoms like *Akshepa* [convulsive movements], *Stambha, Kampa, Gatisanga* and *Vakgraha*, it closely resembles with *Akshepaka* and *Kampavata. Acharya Charaka* describes *Akshepaka* as:[Muhurmuhurakshate angam... - http://Cha.Chi.28/49 :[rigidity][tremor][bradykinesia] [dysarthria] [Frequent convulsions/spasms of the body] due to aggravated *Vata* in *Snayu* and *Dhamani,* often preceded by degeneration in *Majja Dhatu* - which correlates with basal ganglia calcification. Since Fahr's Syndrome involves both *Sharirika* and *Manasika Adhishthana* with *Mastulunga* as *Moola* and is a *Yapya Vatavyadhi, Shodhana* in the form of *Panchakarma* becomes the prime line of management. The present case report attempts to document the efficacy of classical Panchakarma in Fahr's Syndrome understood as *Kampavata* associated with *Akshepaka*.

CASE REPORT

A female patient aged 57 years, who is a known case of Hypertension (3 year) and Diabetes Mellitus 2 (11year)-on regular medication, was apparently asymptomatic 3 years ago. Then gradually she developed involuntary movements of bilateral hand along with slowness of activities associated with Lower back pain & persistently depressed mood, decreased interaction for last 1 year.

The involuntary movement have started insidiously during pregnancy at the age of 30 year, the frequency of seizure was 4-5 episode for 2-3 days. Each attack lasts for five minutes without any loss of consciousness and associated with abnormal movements of limbs. For which she was approached to NIMHANS and prescribed DIAZEPAM in BD dose for 5 years. As satisfactory relief was obtained, the patient had medication in OD dose. After which she did not develop any of the symptoms for 10 years and she discontinued the prescribed medications. Her mother had history of Epilepsy.

In past 3 years, she lost one of her daughter (out of 6 & 2 children died during childhood) and husband. Later, due to mental disturbance, previously mentioned symptoms were reoccurred. For which she had approached Victoria Hospital and diagnosed as PD & prescribed Syndopa 110 mg in BD dose for 1 month. Since there is no improvement, she approached to SJIIM, Bengaluru for further management.

Clinical Findings

Table 1: Showing the Vayatika Vrittanta.

Ahara	Mixed diet
Rasa pradhana	Madhura rasa pradhana sarva rasa
Vihara	Sleeping, sitting
Vyasana	None
Agni	Mandagni
Kostha	Madhyama
Nidra	Disturbed
Emotional status	Stress (pshychogenic)

Table 2: Showing the General Examination.

General appearance	Moderately ill
Pulse rate	92 bpm (Regularly regular, Volume-Normal)
Blood preesure	130/90 mm of hg
Pallor	Absent
Icterus	Absent
Cyanosis	Absent
Clubbing	Absent
Lymphadenopathy	Absent
Edema	Absent

Built	Moderate
Tongue	Alipta
Height	4.9 feet
Weight	47 kg
BMI	22.9kg/m^2

Table 3: Showing the Ashtasthana Pareeksha.

Nadi	Prakrita
Mala	Baddha Mala
Mutra	Atipravritti
Jihwa	Alipta
Shabda	Prakrita
Sparsha	Prakrita
Drik	Prakrita
Akruti	Madhyama

Table 4: Showing the Dashavidha Pareeksha.

Prakruti	Vata-Kapha
Vikruti	Tridoshajanya
Sara	Madhyama
Samhanana	Madhyama
Satmya	Madhura pradhana sarva rasa satmya
Sattva	Avara
Pramana	Madhyama
Ahara Shakti	Avara
Vyayama Shakti	Avara
Vaya	Madhyavastha

SYSTEMIC EXAMINATION

- Respiratory system – Normal vesicular breath sounds heard
- Gastro intestinal system – No abnormalities detected
- Cardiovascular system – s1 s2 Heard, no added sounds
- Central nervous system examinations:-

Higher mental function – conscious, well oreiented to place, person, time. memory is intact.

Cranial nerve – intact

Deep Tendon Reflex- could not be elicited (due to tremor)

Sensory system

Touch - intact

Temperature - intact

Pain- intact

Coordination

Finger nose test - possible

Dysdiadochokinesia - possible

Heel shin test - possible

Glabellar tap test - positive

Tandeem walking – not possible

Motor system

		Right	Left
Muscle bulk	Upper limb	No atrophy	No atrophy
	Lower limb	No atrophy	No atrophy
Muscle tone	Upper limb	Normotonic	Normotonic
	Lower limb	Normotonic	Normotonic
Muscle power	Upper limb	4/5	4/5
	Lower limb	4/5	4/5

Mental status examination

- The patient was well oriented to time, place and person.
- No cognitive impairment (confusion or memory loss that happens more often or getting worse during past 12 months) is observed.
- The patient appearance was ill look with minimum speech.
- The mood was depressed and there is no restlessness.
- Memory (immediate, recent & remote) was intact.
- The patient had no symptoms of hallucination (no auditory, visual, olfactory hallucination).
- Negative personal traits (low extroversion, high neuroticsim) was found.
- Except some depressive features, mental status examination findings were unremarkable. So this patient had not satisfied the diagnostic criteria for depressive disorder, conversion disorder and other somatic or psychiatric illness.

Musculoskeletal examination

- Spine examination

1. Inspection

Curvature – normal

Deformity – absent

Scar mark – absent

2. Palpation

Tenderness – positive at L4 –S1 Vertebral region

Temperature – not raised

Doorbell sign – positive

3. ROM

Restricted flexion and extension of spine (Forward Flexion 30° with pain,

Extension to 10° pain ++)

- Gait – Antalgic gait
- Attitude:

Upper limb – Normal

Lower limb – Normal

- Heel walk & toe walk – Possible with pain

ROGA PAREEKSHA

Nidana panchaka

- Nidana

Utpadaka Nidana – Chinta, Shoka, Dukha Shayyashanat, Bhaya

Viprakrushta Nidana – Rogatikarshanat

- Poorvarupa - Avyakta
- Roopa – Spandana, Stambha, Pralapa, Anidrata, Gatra- Suptata
- Upashaya-Anupashaya – None
- Samprapti

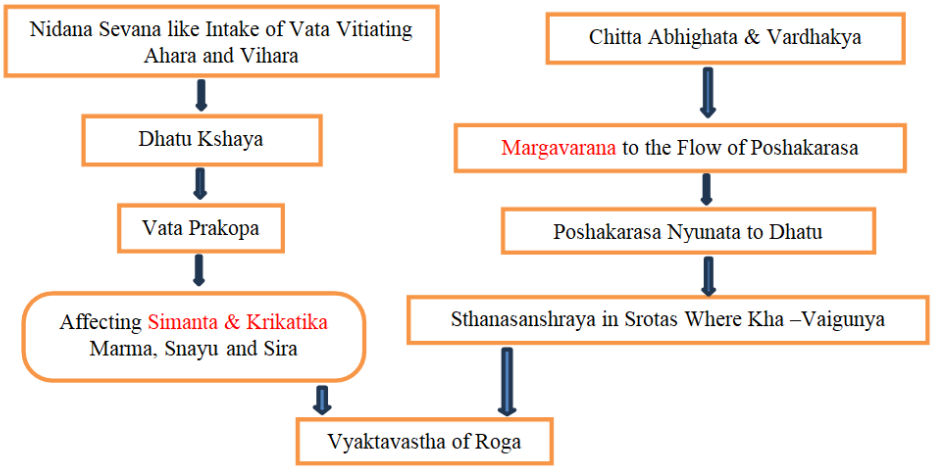

Samprapti ghataka

- Dosha – (manasa) raja, tama (sharira) vyana vayu, pachaka - sadhaka pitta, tarpaka kapha
- Dushya – Manas, Rasa
- Agni – jatharagni vishamata
- Srotas – Manovaha, Rasavaha srota
- Srotadusti – vimarga gamana, atipravrtti, sanga
- Udbhava sthana – hridaya
- Vyakta sthana – mana and sarva shareera
- Roga marga – Madhyama
- Sadhyasadhyata – krichhasadhya

LABORATORY FINDINGS



DEPARTMENT OF RADIO-DIAGNOSIS
DISTRICT HOSPITAL CHIKKABALLAPUR– 562101.

NAME
AGE/SEX
HOSPITAL NO./UNIT
DATE 23/02/2024
C.T. NO.

CT SCAN HEAD&BRAIN (PLAIN)

Technique: Non enhanced helical serial axial sections of brain.

Findings:

- There is evidence of faint calcification in basal ganglia bilaterally.
- The sections of the supratentorial brain do not reveal any area of altered tissue density. The deeper nuclei are normal.
- There is no evidence of SOL / infarct/ acute SDH / EDH / SAH or intra cerebral Hemorrhage seen.
- The ventricular system is normal. No shift of midline structures. Subarachnoid cisterns and sulcal spaces appear normal. No enhancing cisternal / sulcal exudates.
- Mid brain appears normal. Posterior fossa structures appear normal. Fourth ventricle is normal. Both the Cerebelli and cerebellar peduncles are normal. Both internal auditory meati are normal.
- Sella and parasellar regions are normal.
- Bony calvarium is normal. Included sections of PNS are normal.

IMPRESSION

➢ Faint basal ganglia calcification as described above.

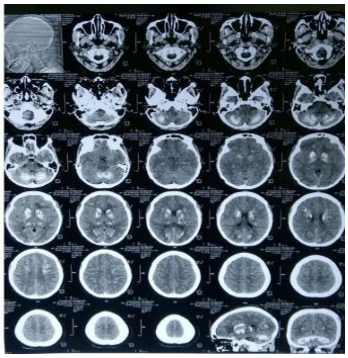

Treatment protocol adopted

Table 5: Showing the treatment protocol adopted.

Name of the procedure	Duration
Sarvanga Abhyanga with *Mahanarayana taila* followed by *Ushnajala Snana*	17-06-2024 to 24-06-2024
Kosthashodhana with Gandharvahastadi Eranda Taila-30 ml	25-06-2024
Nasya with *Ksheerabala 101 Avarti taila*	26-06-2024 to 09-07-2024
Oral medicine during the treatment - Ashwagandha vati-1 tab BD/AF & Saraswatarista -10 ml BD/AF	At the time of discharge - *Kalyanaka Ghrta* 10 ml Empty stomach in morning- with Lukewarm water

RESULT

Table 6: Showing the result.

	Case Report	
	BT	**AT**
Subjective criteria	Episode of seizure once in each 2 days.	No history of seizure in last 15days.
Low back pain	Severe	Reduced by 50%
Mood	• Depressed • No eye contact • Not answering • No interaction with other patients, Doctors Isolated	• Cheerful • Eye contact • Smiles occasionally • Interacts with other as well as participation in groups
Speech	Low volume, slow & less talkative	Normal speed, clear, initiates conversation
Sleep	Disturbed	Sound (6-7 hrs)

DISCUSSION

- Fahr's syndrome is also known as fahr's disease, familial idiopathic basal ganglia calcification and primary familial brain calcification.
- It is a rare neurological disorder characterized by bilateral calcifications of areas in the brain including, basal ganglia (most commonly the globus pallidus), cerebellum (most commonly the dentate nucleus), thalamus, hippocampus, cerebral cortex.
- Clinical manifestations of this disease incorporate a wide variety of symptoms, ranging from neurological symptoms of extrapyramidal system to neuropsychiatric abnormalities of memory and concentration to movement disorders including Parkinsonism and tremors amongst others.
- Complications include stroke, dementia, dystonia as well as systemic complications.

So, here Panchakarma therapy acts as supportive neuro-rehabilitative management rather than curative. Goal of the treatment in Fahr's Syndrome involves.

1. Vata Shamana &Kapha- Avarana Bhedana i.e.Srotoshodhana as well as Vatanulomana.
2. Neuro-protection & Medhya effect.
3. Improvement in Motor functions.
4. Rasayana & Dhatu Poshana
5. Quality of life improvement & Slow Progression of disease

Sarvanga Abhyanga

Kampavata is *Kevala Vata Janya Vyadhi* with *Kapha Avarana* and *Dhatu Kshaya* _ - Charaka Chi. 28/18. *Vata* resides in *Twak - Vayu: Sparshanendriya*. *Abhyanga* is first line treatment for *Vata - Abhyanga Marutaghnam* [Cha. Su. 5/85-

86]. It does *Vata Anulomana*, *Kapha Avarana Bhedana* and *Srotomardavata*. *[Majja][Ojas*]. In *Kampavata*, *Chala Guna* of *Vata* increases causing *Kampa*, and *Sheeta/Ruksha* Guna causes *Stambha*/Rigidity. *Abhyanga* with *Ushna, Snigdha, Guru Guna Dravya* directly counteracts this. As there was involvement *of Kapha* and *Vata* in the *Samprapti, Mahanarayana Taila Abhyanga* was adopted.

Mahanarayana Taila: *Balya, Brimhana, Vata-hara*, has proven neuroprotective action.

Abhyanga provides

- Tactile proprioceptive stimulation - reduces rigidity and bradykinesia by improving somatosensory feedback.
- Increases cutaneous blood flow, reduces cortisol, improves dopamine signaling indirectly via relaxation of HPA axis.
- Stimulates peripheral nerves and improves muscle perfusion, reducing *Kampa* and *Gaurava*.
- Daily Abhyanga improves sleep, constipation, anxiety - which are non-motor symptoms of *Kampavata*.

Therefore, in *Kampavata*, *Snehana* in form of *Sarvanga Abhyanga* acts both at central and peripheral level. At peripheral level it nourishes *Mamsa* and *Majja Dhatu* and reduces *Stambha* and *Kampa*.Thus *Abhyanga* is not just a *Purvakarma* but a *Pradhana Shamana* therapy for *Kampavata*, especially when done with *Vatahara Taila* followed by *Swedana* in the form of *Ushna jala Snana*. It improves quality of life without adverse effects.

Kosthasodhana

Kostha Shodhana was performed as *Poorvakarma* of *Nasya* to achieve *Niramavastha* and *Vatanulomana.* In *Kampavata,* due to presence of *Krura Kostha* and *Malabaddhata,* direct *Brimhana Nasya* may lead to *Agnimandya* and *Nasya Ayoga. Mridu Kostha Shodhana* with *Gandharva Hastadi Eranda Taila* helped in clearing *Avarana* and facilitated better absorption of *Nasya Dravya* through *Shringataka Marma*.

If *Mala Sanchaya* in *Kostha*, *Vata* gets *Pratiloma* - *Nasya Dravya* will not reach *Shiras*, it will cause *Shirashoola, Hrillasa, Kasa, Shwasa*. Reference-Ashtanga Hridaya Su. 20/19 - *Snigdha Swinna Urdhva-Shodhita.....*

Nasya

Kampavata is considered as *Urdhva Jatrugata Vata Vyadhi*. According to Ach.Charaka, *Nasa hi Shiraso Dwaram* - *Nasya* is the prime route for drug delivery to *Shiras*. Hence *Nasya* is considered as *Pradhana Karma* in *Kampavata.*

In this study, *Brimhana Nasya* was adopted. In *Dhatukshaya Janya Kampavata* seen in old age, *Shodhana Nasya* with *Tikshna Dravya* is contraindicated as it will further aggravate *Vata* and increase *Kampa. Brimhana Nasya* with *Kshirabala 101 avarti Taila* provides *Brimhana, Balya* and *Medhya* effect.

After *Urdhwajatru preadesha Abhyanga* and *Patasweda* over *Shiras, Lalata* and *Greeva, Brimhana Nasya* with *Ksheerabala Taila* in *Madhyama Matra* 4 drops per nostril was given for 14 days (started with 2 drops per nostril – after 3 days 3 drops per nostril for 5 days and then continued with 4 drops per nostril). This is in accordance with *Sharangadhara's* reference of *Masha Taila Nasya* in *Kampavata* and *Ashtanga Hridaya Su. 20/1* which states *Nasya* is *Shreshtha* for *Urdhva Jatru Vikara.*

Drug administered via nasal route reaches the olfactory nerve, olfactory bulb and limbic system through nose-to-brain pathway, bypassing the Blood Brain Barrier. It stimulates *Shringataka Marma* [cavernous sinus plexus] which is rich in vascular and neural network, thereby improving basal ganglia function and dopamine regulation. Clinically this was observed as reduction in *Lalasrava*, improvement in facial rigidity and masked facies as well as speech.

Ksheerabala 101 avarta Taila

Ksheerabala 101 Avarti Taila for *Nasya* is considered as *Avara Matra, Maha Virya* - very potent for *Vata. Normal Ksheerabala Taila = Bala + Ksheera + Tila Taila* cooked 1 time.

In Sahasrayogam - Taila Prakarana: 101 Avarta = Same *Taila* is cooked 101 times repeatedly with fresh *Bala Kalka* and *Ksheera*. Each *Avartana* increases *Sukshmata, Vyavayi* and *Vata-hara* potency. Potency becomes 101 times more, so dose is very less.

It acts as Samprapti Vighatana Chikitsa. *Kampavata = Gambhira Dhatugata Vata + Majja Kshaya + Mastulunga Kshaya*. Normal *Taila* cannot reach *Majja*. As 101 Avarti is *Sukshma Srotogami, Yogavahi, Achintya Virya* - reaches *Majja Dhatu* and Basal Ganglia.

Therefore, *Ksheerabala 101 Avarti Taila* was selected for *Nasya* due to its *Sukshma, Vyavayi* and *Vatahara* properties attained by 101 times *Paka*. In *Kampavata* which is a *Madhyama Rogamarga* and *Majja Dhatugata Vata Vyadhi*, ordinary *Sneha* fails to penetrate. 101 Avarti Taila by virtue of repeated *Avartana* attains increased potency in *Alpa Matra* and acts as *Brimhana* and *Rasayana* for *Mastishka. Bala* as main ingredient has documented anti-Parkinsonian and neuroprotective activity. Clinically it showed marked improvement in *Kampa, Stambha, Vak Vikriti* and *Lalasrava*.

Kalyanaka Ghrita

After *Nasya*, which provides direct *Snehana* to *Mastulunga, Shamana Snehapana* with *Kalyanaka Ghrita* was planned at discharge to sustain the neuroprotective and *Medhya* effect. *Ghrita* is considered as best for *Mastishka – "Ghritam Medhya", Balyam, Vatahara* and is the best *Yogavahi* for *Medhya* drugs. *Kalyanaka Ghrita* with its ingredients having *Medhya*, Anxiolytic and antidepressant activity helps in management of non-motor symptoms of *Kampavata* like anxiety, depression and sleep disorder which are part of *Manovaha Srotas Dushti*. Moreover, continuous low dose *Ghrita* acts as *Rasayana* for *Majja Dhatu* and prevents further degeneration. This follows the principle of *Shodhana Purvaka Shamana* and *Shamana* after *Nasya* for long term maintenance.

Ashwagandha Vati-* For *Sharirika Vata

Chief Ingredient- *Ashwagandha* act as *Balya, Brimhana, Vatahara, Rasayana, Mamsa-Majja Bala Kara.*

-Anti-Parkinsonian - GABA mimetic, increases dopamine in striatum, reduces neuroinflammation, adaptogen, improves muscle strength and reduces *Stambha* and *Gaurava.*

- Indication in *Kampavata: Dhatu Kshaya, Kampa, Stambha, Dourbalya, Nidranasha.*

Saraswatarista- For Manasika Vata

In Bhaishajya Ratnavali - Rasayanadhikara 73/147-152

Ingredients*: Brahmi, Shatavari, Vidari, Ashwagandha, Haritaki, Bala, Vacha, Shatapushpa, + Swarna Patra.*

All are Medhya, Vatahara, Smriti-Buddhi Prada.

- Reduces anxiety, depression, fear - *Chittodvega, Vishada.*
- Improves speech - *Vakshuddhi - Gadgada* in *Kampavata*
- Improves sleep and memory
- *Arishta* form - quick absorption, *Deepana*, corrects *Agni* which is mandatory with *Ghrita Sevana.*

CONCLUSION

Kampavata is being *Urdhva Jatrugata Dhatukshaya Janya Vata Vyadhi* requiring *Brimhana* line of treatment. *Sarvanga Abhyanga* and *Ushna Jala Snana* followed by *Mridu Kostha Shodhana* helps in *Vatanulomana*, *Srotomukha Vishodhana* and prepares body for *Nasya*. *Brimhana Nasya* with *Ksheerabala 101 Avarti Taila* is *Pradhana Karma* and effective in motor and non-motor symptoms via nose-to-brain pathway. *Shamana* with *Kalyanaka Ghrita*, *Ashwagandha Vati* and *Saraswatarishta* provides synergistic action on *Sharirika and Manasika Lakshana*.

Combined protocol ***Abhyanga + Ushna Jala Snana → Kostha Shodhana → Ksheerabala 101 Nasya → Shamana Snehapana*** is safe and effective holistic management for *Kampavata*. The conclusions were drawn after logical interpretation of the results obtained in the preceding clinical study.

REFERENCES

1. Manyam BV. What is and what is not 'Fahr's disease'. Parkinsonism Relat Disord, 2005; 11: 73-80. - Most cited reference to differentiate Fahr's disease vs Syndrome.
2. Saleem S, Aslam HM, Anwar M, et al. Fahr's syndrome: literature review of current evidence. Orphanet J Rare Dis, 2013; 8: 156.
3. Donzuso G, Mostile G, Nicoletti A, Zappia M. Basal ganglia calcifications [Fahr's syndrome]: related conditions and clinical features. Neurol Sci, 2019; 40: 2257-2263.
4. Batla A, et al. Fahr's syndrome. N Engl J Med. - For imaging reference.[2][11Agnivesha, Charaka, Dridhbala. Charaka Samhita, Sutra Sthana, Maharogadhyaya, Verse 11. Acharya YT, editor Reprint ed. Varanasi: Chaukhambha Orientalia: 2015, p.113 [Crossref] [PubMed]/Google Scholar)
5. Madhavakara. Madhava Nidana. Upadhyaya Y, editor. Vol 1. Varanasi: Chaukhambha Prakashana: (year not specified). p.494 (Crossref] [PubMed] [Google Scholar]
6. Patel K, Gadewar M, Tripathi R, Prasad SK, Hemalatha S. Sida cordifolia Linn: a review of its traditional uses, phytochemistry and pharmacological properties. J Ethnopharmacol, 2011; 133(3): 556-63. doi:10.1016/j.jep.2010.10.004 [Crossref][PubMed][Google Scholar]
7. Meera S, Kumar A, Kalavathy S. Evaluation of Bac depressant activity of Ksheerabala (101) Thailarm experimental animal models. AYU, 2012; 33(1): 11 Intro doi:10.4103/0974-8520.100329 [Crossref][PubMed][Go Scholar]